Journal of the American Association for Laboratory Animal Science
Vol 45, No 1
January 2006
Pages 52–56

Surgical Technique for Long-Term Cecal Cannulation in the Yucatan Minipig (*Sus scrofa domestica*)

Diana L. Eubanks,*[*] Robert Cooper, and J. Gregg Boring

Measurements of standardized ileal digestibility yield more useful results than do those of fecal digestibility. To that end, cecal cannulation of the pig has been performed extensively in an attempt to model the digestive processes of humans. Here we introduce a technique for the placement of a permanent cecal cannula with a silicon port that is larger in diameter than those previously described in the literature. A large lumen offers several advantages, most notably ease in collection of larger samples and introduction of materials into the cecum. To date, this technique has been used successfully to cannulate 39 Yucatan minipigs at our institution. Long-term, there have been no major complications with the procedure or cannulas.

Abbreviation: IM, intramuscular

Experimental animal models have proven beneficial in the study of numerous animal and human physiologic and pathologic conditions. In particular, cecal cannulation has been used extensively to study nutrient digestion, absorption, and gastrointestinal transit times in swine. Placement of a long-term cecal cannula allows repeated measurements in individual animals, thus reducing the number of animals euthanized compared with those with more traditional techniques such as the slaughter method, and enhancing the statistical power of the experiment. Samples collected from a cecal cannula represent real-time processes and are more reflective of small intestinal physiology than are fecal samples that have been altered by the large intestine. In addition, test materials can be introduced into the cecum for large intestinal studies. Recently, the beneficial effects of both prebiotics and short-chained fatty acids have been studied by using cannulated pigs.[3] Cecal access also has permitted infusion of various compounds into the large intestine, sampling for in vitro fermentation of cecal contents,[11] evaluation of ruminal undigested protein,[7] performing repeated endoscopies and biopsies,[4] as well as collection of other data.

The Yucatan minipig (*Sus scrofa domestica*) has proven to be an appropriate model for studies of human digestion and absorption, including the testing of oral drug delivery systems and oral absorption mechanisms.[1,6] Anatomically and microscopically, the tissues of the gastrointestinal tract in Yucatan minipigs closely resemble those of humans.[1,6] In addition, the Yucatan's tractable nature and relatively small size have made it useful for long-term studies.[1,8] In the past, genetic selection for altered glucose metabolism made certain lines of these pigs useful animal models for human diabetes mellitus.[8]

Measurements of ileal digestibility yield more useful results than do those of fecal digestibility, especially during study of prececal digestive processes.[9] A variety of cannula designs and cannulation techniques have been previously described including re-entrant cannulae, simple T cannulae, steered ileocecal valve cannulae, and postvalve T cecal cannulae. High-fiber diets have been related to cannula blockage,[12] emphasizing the need for a large lumen and a cannula that does not interfere with the flow of digesta. A wider opening can accommodate larger sample sizes and facilitate the introduction of test materials into the cecum.

Techniques for the placement of smaller cecal cannulas and for cannulas with a shorter functional time have been described.[2-4,6,10,13] Here we introduce and describe in detail the surgical placement of a larger permanent cecal cannula in 15 Yucatan minipigs. Since 1991, cannulas of this type have been placed in a total of 41 Yucatan minipigs at our institution, and in some cases, maintained for more than 10 y.

Materials and Methods

Animals and diets. All procedures were approved by the Mississippi State University Institutional Animal Care and Use Committee and were performed by veterinarians in facilities accredited by the Association for the Assessment and Accreditation of Laboratory Animal Care, International. Fifteen certified pathogen-free (brucellosis, tuberculosis, pseudorabies, and hog cholera) Yucatan minipigs, obtained from the Charles River Colony (Windham, ME), underwent permanent cecostomy. At the time of the procedure, they ranged in age from 6 to 7 y and weighed an average of 71.5 kg. Immediately after cecostomy, a silicon port with a removable cap (Omni Technologies, Greendale, IN) was positioned in the stoma, providing direct access to the cecum and colon.

The animals were housed at the Biomedical Research Center of Mississippi State University in individual cages (4 × 8 ft.) lined with plastic fascia board and in a room on 12:12-h light: dark cycle. The temperature was maintained at 22 to 23 °C. All animals received 3 cups of standard pig chow (Purina 5082, LabDiet, Richmond, IN) twice daily, with water available ad libitum. Facility and housing improvements, such as the smooth, plastic fascia board placed inside the individual pens, served to reduce the displacement of the cannulas. In addition, social enrichment of the experimental animals, including the introduction of basketballs for daily play, was instituted to alleviate the anxiety associated with being housed in a research colony.

Received: 26 July 2005. Revision requested: 21 Sept 2005. Accepted: 21 Sept 2005.
Biomedical Research Center, College of Veterinary Medicine, Mississippi State University, Mississippi State, Mississippi.
[*]*Corresponding author. Email: deubanks@cvm.msstate.edu*

Figure 1. The cannula, made of molded liquid silicon with a threaded plastic insert, is placed within the cecal stoma.

Description of cannula. The cannula made of molded liquid silicon with a threaded plastic insert (Omni Technologies, Greendale, IN) permits collection of cecal contents. An oval 11.6×10.4-cm inner flange and a round 10.0-cm outer flange are connected by a plastic barrel measuring 4.0 cm in length. The barrel lumen is threaded, measures 3.9 cm in diameter, and is closed by a threaded plastic cap (Figure 1).

Surgical procedure. Prior to surgery, each pig was held without food for 18 h; water consumption was not restricted. Pigs were premedicated with a combination of Telazol (Fort Dodge Laboratories, Fort Dodge, IA) reconstituted with ketamine (Ketaset, Ft. Dodge Laboratories) and xylazine (Phoenix Scientific, St. Joseph, MO). Briefly, 250 mg ketamine and 250 mg xylazine were added aseptically to a 500-mg vial of Telazol and then administered intramuscularly (IM) at a rate of 0.01 to 0.02 ml/kg body weight (equal to 0.5 to 1 mg/kg ketamine, 0.5 to 1 mg/kg xylazine, and 1 to 2 mg/kg Telazol). Atropine also was administered IM at 0.04 mg/kg. The empirical decision not to use prophylactic antibiotics was made because the surgical time was less than 2 h. An over-the-needle, 20-gauge (length, 2 in.) catheter was placed in an auricular vein. Each pig was preoxygenated with a facemask, and anesthesia was induced with 5 mg/kg thiopental (Abbott Labortatories, North Chicago, IL) administered intravenously to allow orotracheal intubation. Anesthesia was maintained with isoflurane (IsoFlo, Abbott Laboratories) in oxygen administered via a circle breathing system. Isoflurane concentration was adjusted as needed in light of monitored parameters and response to surgical stimulation. Pigs were mechanically ventilated at 15 ml/kg tidal volume and 6 to 10 breaths per min for the duration of the surgery. After induction of anesthesia but before skin incision, 13.5 to 15 μg/kg buprenorphine (Reckitt & Coleman, Richmond, VA) was administered intravenously. Anesthesia monitoring included indirect blood pressure, body temperature, heart rate, electrocardiography, pulse oximetry, capnography, and visual assessment of anesthetic depth.

Pigs were placed in right lateral recumbency on a circulating warm water heating pad. The left caudal flank area was clipped and surgically prepped with chlorhexidine scrub from midthorax cranially to midthigh caudally and from the dorsal midline to just lateral to the mammary chain ventrally. The pig then was moved into the surgery suite, where a final chlorhexidine scrub of the surgical site was performed. A balanced electrolyte solution (lactated Ringers solution at 10 ml/kg hourly) was administered through the intravenous catheter.

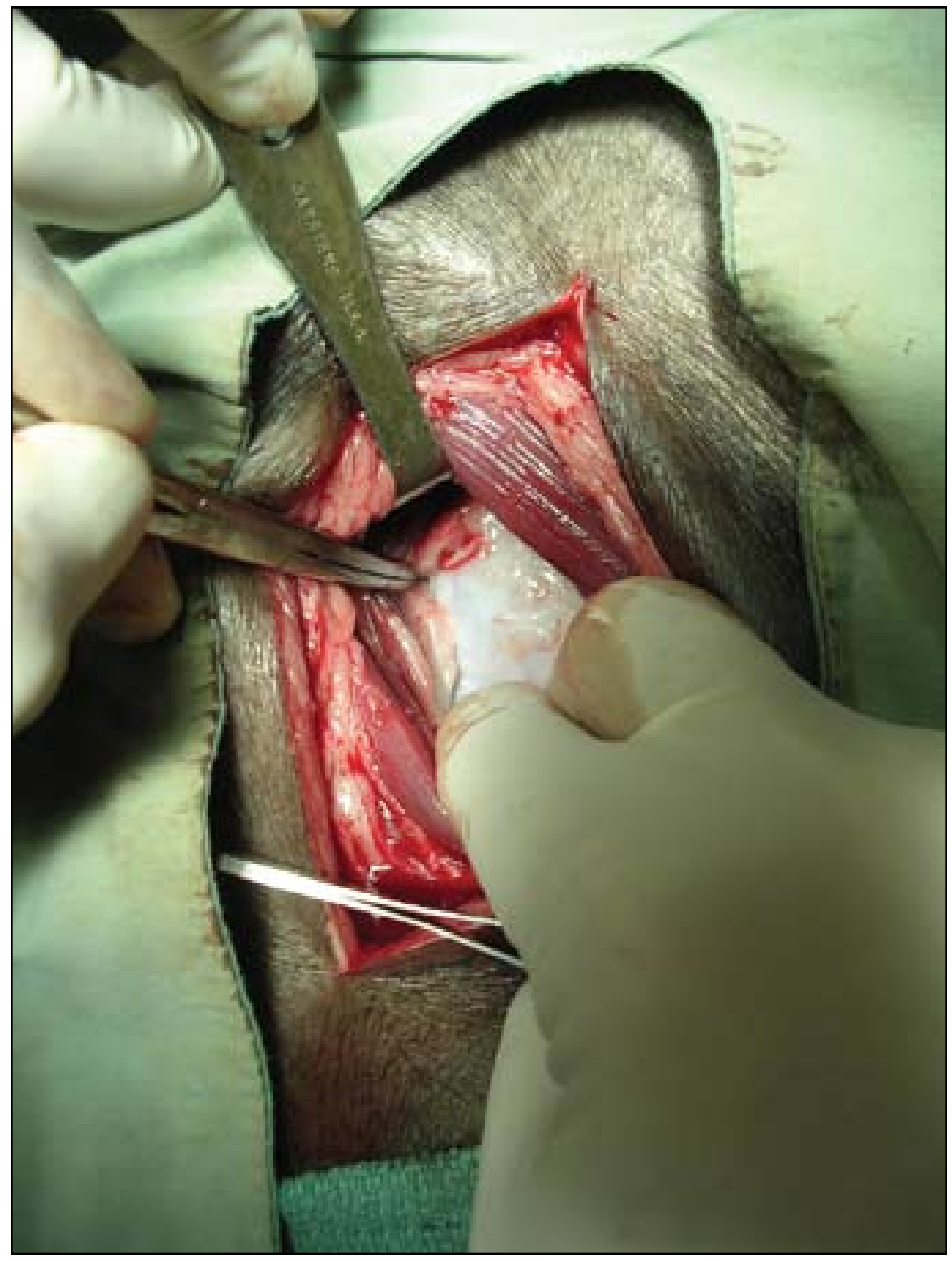

Figure 2. By using a grid approach, the deep layers of the abdominal wall were opened exposing the peritoneum.

A 15-cm skin incision was made with a #10 scalpel blade, beginning immediately caudal to the last rib and approximately 5 cm ventral to the lumbar transverse process and extending in a cranioventral direction parallel to the costal arch. The cecostomy was centered at the midpoint of this line. The incision was continued through the subcutaneous tissues and the cutaneus trunci muscle, exposing the external abdominal oblique muscle. By using a grid approach, the deep layers of the abdominal wall (external abdominal oblique, internal abdominal oblique, and transversus abdominis muscles) were opened, exposing the peritoneum (Figure 2).

After the peritoneum was incised, the cecum was isolated and exteriorized. The size and location of the cecal wall stoma were established by placing the outer edge of the cannula cap on the lateral side of the cecum in a location that would allow room for the inner flange to expand within the cecum while causing minimal stress on the cecal wall. Four stay sutures were placed in the cecum equidistant around the cap by using 2-0 polydioxanone suture (PDS II, Ethicon, Somerville, NJ). The cecum was returned to the peritoneal cavity, and the stay sutures remained outside of the cavity to facilitate retrieval of the cecum (Figure 3). The skin edges were approximated with towel clamps, and the cannula cap was centered over the midpoint of the skin incision to establish the size and location of the body wall stoma. A scalpel was used to remove a circular portion of the skin, subcutaneous tissue, and cutaneus trunci muscle that was the same diameter as the cap (Figure 4).

Closure of the body wall and construction of the stoma was begun by suturing the cutaneus trunci muscle with 2-0 polyglactin 910 suture (Vicryl, Ethicon) in a simple continuous pattern

Figure 3. Stay sutures of 2-0 poly-dioxanone (PDS II) were placed along the serosal surface of the cecum to approximate the location of the cecal wall stoma. The cannula cap was used to establish the size of the stoma.

Figure 4. With the cannula cap as a template, a circular portion of the skin and subcutaneous tissues were removed.

from the dorsal and ventral extents of the skin incision to the edge of the stoma. The skin was closed in a similar manner by using 3-0 polyglactin 910 in a continuous subcuticular pattern. The grid incision was not closed.

The cecum was checked for proper anatomical orientation to ensure that the flow of ingesta would not be compromised and that minimal stress would be placed on the tissues. The serosal surface was anchored to the cutaneus trunci muscle with 2-0 polyglactin 910 suture at 4 equidistant sites by using the 4 cecal stay sutures as a template for the cecal wall stoma. A simple continuous pattern was used to attach each of the 4 quadrants of serosa to muscle tissue, ensuring a firm attachment prior to incision of the cecum (Figure 5). The cecum was incised such that the cut edge could be sutured to the skin in an approximating pattern by using 3-0 polyglactin 910 (Figure 6). The opening into the cecum was digitally palpated to assess whether a portion of the inner flange of the cannula might need to be trimmed to ensure a uniform fit.

The cecal cannula (Omni Technologies) then was prepared for placement within the stoma. The dorsal and ventral aspects of the inner flange were trimmed to avoid creating undue tension on the cecal wall. The long axis of the inner flange of the cannula was placed parallel to the long axis of the cecum, in

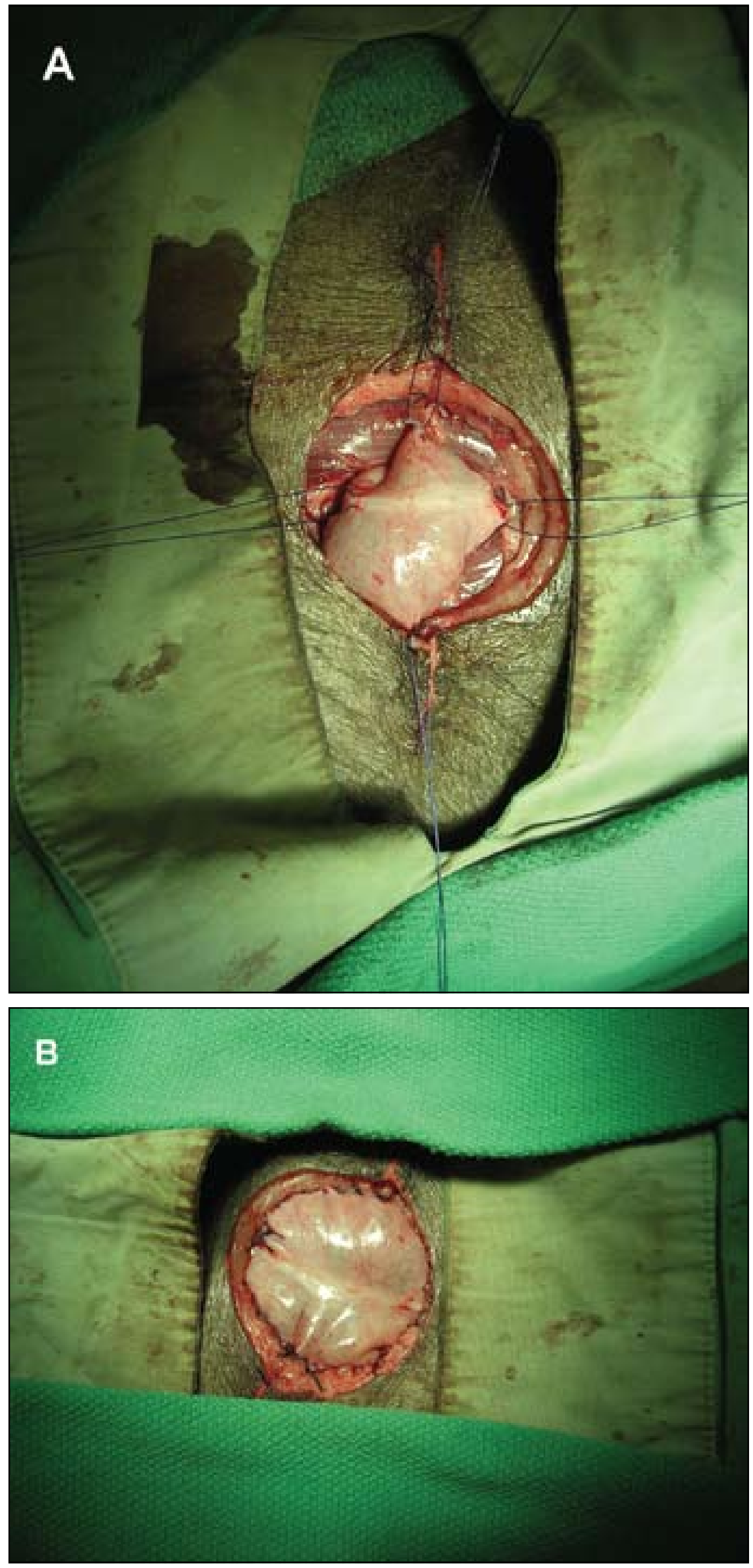

Figure 5. (A) The serosal surface of the cecum was anchored to the cutaneus trunci muscle by using 2-0 polygalactin 910 (Vicryl) and 4 anchor points. (B) The quadrants then were closed using 2-0 Vicryl in a simple continuous pattern.

a craniocaudal direction. During placement of the cannula, the free edge of the longer dimension of the inner flange was inverted through the barrel portion of the cannula (Figure 7). This maneuver folded the inner flange so that one half could be inserted through the stoma. Once positioned in the stoma, the inverted edge (the other half) was pushed back into the cecal lumen, thereby opening the inner flange. The surgeon inserted a finger through the cannula to palpate for any areas of the cecal wall that were stretched excessively. If problem areas were noted, the cannula was removed and the inner edge trimmed with scissors (Figure 8).

Figure 6. The cecum was incised such that the cut edge could be sutured to the skin in an approximating pattern using 3-0 polygalactin 910 (Vicryl).

Figure 7. Prior to placement of the cannula, the inner flange was inverted through the barrel portion, to facilitate insertion into the stoma.

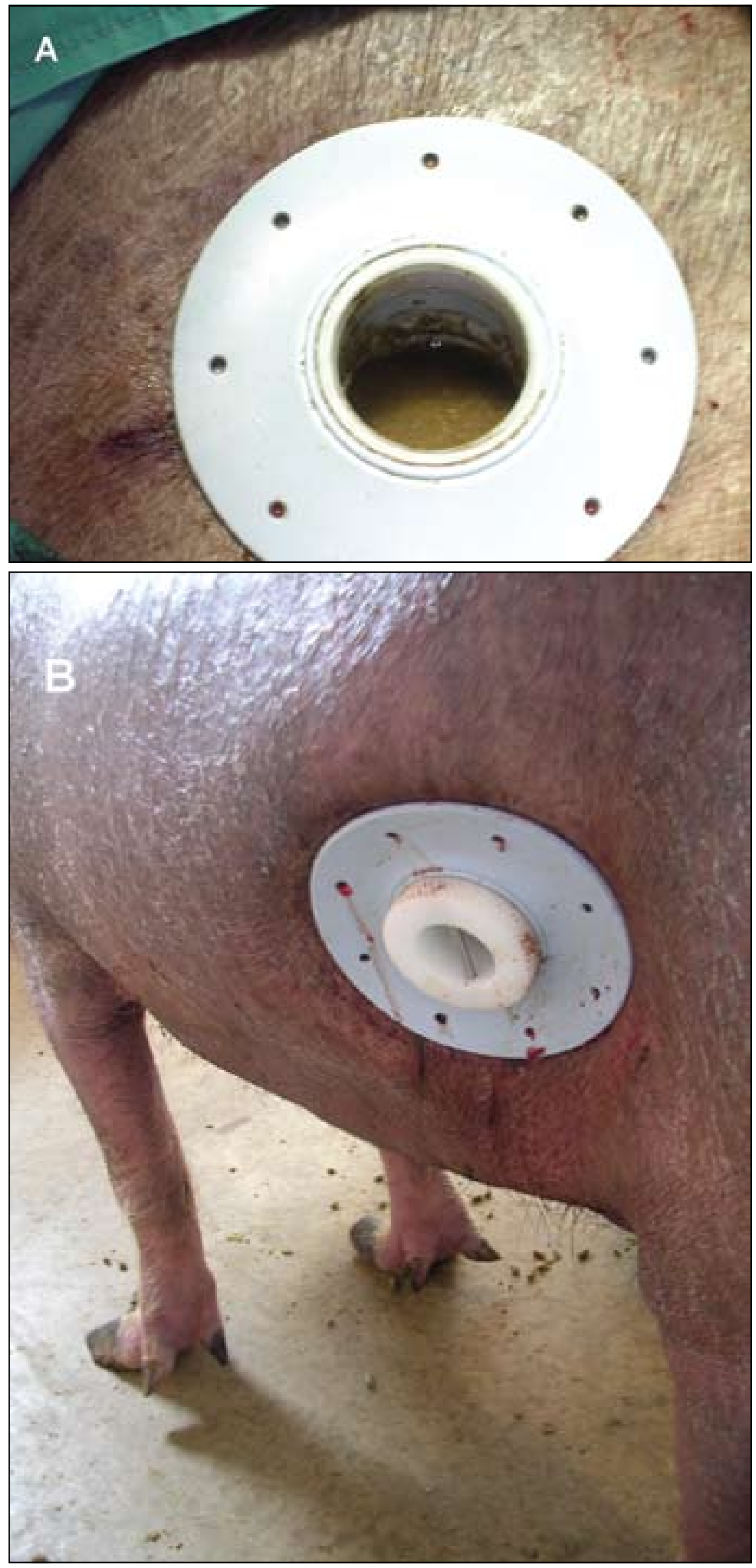

Figure 8. The cannula in place. (A) Without the cap. (B) With the cap.

Postoperative care. Pigs were returned to their cages prior to extubation. Postoperative monitoring during the first 24 h included temperature, heart rate, and pain assessment. Buprenorphine HCl (13.5 to 15 µg/kg; Buprenex, Reckitt & Coleman) was given IM at 8, 16, 24, and 32 h after induction of anesthesia. Pigs were monitored visually for signs of pain or discomfort, including reluctance to lie down, vocalization when touched, and anorexia. Additional doses of buprenorphine were administered IM if deemed appropriate. Nonsteroidal anti-inflammatory drugs were avoided because of the history of gastric ulceration in these pigs, especially during times of stress. The morning after surgery, all pigs were returned to their normal rations. In most cases, pigs would consume about half of this ration during the first 24-h period, gradually resuming normal appetites by 3 to 4 d postsurgery. The skin surrounding the cannula was cleaned 2 to 3 times daily for the first week by using either hydrogen peroxide or warm water prior to application of Dermagen ointment (The Butler Company, Columbus, OH) to avoid irritation of the skin from leakage of ingesta.

Results

Of the 15 pigs sited in this study, 14 recovered from surgery. In addition, 3 pigs vomited during recovery from anesthesia; 2 of these 3 animals developed respiratory symptoms consistent with aspiration pneumonia, including cough, lethargy, and fever. These 2 pigs were placed on 10 mg/kg amoxicillin (Amoxi-tabs, Pfizer Animal Health, New York, NY) and 5 mg/kg cimetidine crushed and mixed into a suspension; this suspension was given orally every 12 h. The cimetidine was continued for 10 d. In both cases, amoxicillin was discontinued after 3 d, and 2.2 mg/kg Cetiofur HCl (Excenel, Pharmacia & Upjohn, New York, NY) was given IM once daily for 3 d. Buprenorphine HCl (15 µg/kg; Buprenex, Reckitt & Coleman, Richmond, VA) was given IM every 12 h for an additional 3 to 6 doses only in these 2 pigs, as they exhibited signs of pain. One pig recovered after 5 d of treatment, whereas the other died 5 d postoperatively. A necropsy was performed, and findings were consistent with aspiration pneumonia. Pathologists noted that the cannula was intact though some areas of devitalized tissue were present around the rim of the cannula. The 3rd pig that vomited did not seem to be affected and recovered normally.

Since 1991, 26 other Yucatan minipigs (in addition to the 15 pigs described earlier which were cannulated in 2005) have undergone this same surgical procedure. Presently, 3 of these 26 pigs are still being used in fiber studies. The remaining 23 pigs have been euthanized for reasons unrelated to the procedure, including arthritis and cancer. A total of 17 pigs are still alive and involved in research.

Discussion

Here we describe in detail the surgical procedure performed recently in 15 Yucatan minipigs. However, since 1991, a total of 41 pigs have undergone this procedure at our institution. Follow-up reports from researchers indicate 17 of the 41 pigs (including 14 of the 15 animals cannulated recently) are alive and being used in various research capacities. Of the 17 pigs, 3 have been cannulated for more than 5 y. One of the 15 pigs recently cannulated died 5 d postoperatively due to complications related to aspiration pneumonia. The pathologists' observations of small amounts of devitalized tissue around the cannula are consistent with our observations while monitoring the healing surgical site. In approximately 80% of the pigs, a small amount of devitalized tissue sloughed from around the surgical site between 10 and 14 d postoperatively. This tissue apparently is a portion of the mucosa that is exteriorized and does not cause a problem when it is shed.

The empirical decision not to use prophylactic antibiotics was made because the surgical time was less than 2 h. There were no infections except for those associated with possible aspiration, and these were treated on a case-by-case basis.

Researchers reported no major problems with long-term use or maintenance of the cannulas, and some pigs have been maintained for more than 10 y with the cannula intact. In some pigs, the cannula has become displaced, but in most cases, it was reinserted into the existing stoma in the same manner in which it was originally inserted and without sedation. On 2 occasions, sedation was required; this was performed as described earlier in this article, except that the pigs were not intubated and were not placed on gas anesthesia. Digesta occasionally leaked from the cecostomy site, but this leakage did not in any way affect the quality of life for the animal. In the current colony of pigs, samples sizes and availability often vary among pigs, and this variation likely reflects the physiologic variations of individual animals and not a problem with the cannula itself.

This procedure has proven successful for long-term cecostomy maintenance and cannulation in the Yucatan minipig. The cannula requires very little maintenance beyond the first 3 wk postsurgery, and the opening is relatively large, which is an advantage when collecting digesta or introducing test materials into the cecum. Test samples are collected by removing the cannula cap and allowing ingesta to flow into a plastic or paper cup. The large lumen size permits free flow of ingesta and eliminates the need for placing an instrument or collection device (such as a syringe or spatula) into the cecum, thus avoiding damage to intestinal mucosa or alteration of the sample.

Techniques for the placement of smaller cecal cannulas and for cannulas with a shorter functional time have been described.[2-4,6,10,13] Some cannula designs such as the T cannula and those with a narrow barrel are not suitable for diets high in fiber because of poor flow through the cannula barrel.[10,12] Because many of the dietary studies performed in these pigs are used to assess fiber digestion, these cannulas would not be desirable.

References

1. **Crowell MD, Musial F, French W, Kittur D, Anderson D, Whitehead WE.** 1992. Prolonged ambulatory monitoring of colonic motor activity in the pig. Physiol Behav **52:**471–474.
2. **Easter RA, Tanksley TD Jr.** 1973. A technique for re-entrant ileocecal cannulation of swine. J Anim Sci **36**:1099–1103.
3. **Fleming SE, Fitch MD, Chansler MW.** 1989. High-fiber diets: influence on characteristics of cecal digesta including short-chain fatty acid concentrations and pH. Am J Clin Nutr **50:**93–99.
4. **Hamilton CR, Dove CR, Zinn GM, Veum TL.** 1985. Simultaneous cecostomy and ileal cannulation with a modified flexible T-cannula in gilts. Am J Vet Res **46:**942–944.
5. **Jacobson M, Lindberg JE, Lindberg R, af Segerstad CH, Wallgren P, Fellstrom C, Hulten C, Jensen-Waern M.** 2001. Intestinal cannulation: model for study of the midgut of the pig. Comp Med **51:**163–170.
6. **Kurihara-Bergstrom T, Woodworth M, Feisullin S, Beall P.** 1986. Characterization of the Yucatan miniature pig skin and small intestine for pharmaceutical applications. Lab Anim Sci **36:**396–399.
7. **Mustafa AF, Qiao SY, Thacker PA, McKinnon JJ, Christensen DA, Chaplin RK.** 2000. Assessment of the value of cannulated pigs for measuring intestinal protein digestibility of ruminal undegraded protein of canola meal. Can J Anim Sci **80:**519–522.
8. **Panepinto LM, Phillips RW.** 1986. The Yucatan miniature pig: characterization and utilization in biomedical research. Lab Anim Sci **36:**344–347.
9. **Pedersen C, Boisen S.** 2002. Establishment of tabulated values for standardized ileal digestibility of crude protein and essential amino acids in common feedstuffs for pigs. Acta Agric Scand A Anim Sci **52:**121–140.
10. **Rodhouse SL, Herkelman KL, Veum TL, Zinn GM.** 1988. A flexible T-cannula for ileal cannulation of 10 to 20 kg pigs. Lab Anim Sci **38:**92–94.
11. **Smiricky-Tjardes MR, Grieshop CM, Flickinger EA, Bauer LL, Fahey JGC.** 2003. Dietary galactooligosaccharides affect ileal and total-tract nutrient digestibility, ileal and fecal bacterial concentrations, and ileal fermentative characteristics of growing pigs. J Anim Sci **81:**2535–2545.
12. **Stein HH, Shipley CF, Easter RA.** 1998. Technical note: a technique for inserting a T-cannula into the distal ileum of pregnant sows. J Anim Sci **76:**1433–1436.
13. **Zhang YC, Jorgensen H, Fernandez JA, Knudsen KEB.** 2004. Digestibility of carbohydrates in growing pigs: a comparison between the T-cannula and the steered ileo-cecal valve cannula. Arch Anim Nutr **58:**219–231.